

The Prognostic Significance of P16 Immunohistochemical Expression Pattern in Women with Invasive Ductal Breast Carcinoma

Alireza Rezaei¹, Navidreza Shayan¹, Saman Shirazinia¹, Sara Mollazadeh¹,
Negin Ghiyasi-Moghaddam*¹

Abstract

Background: Breast cancer is the most common malignancy in women worldwide. The p16 protein is a cell cycle regulator and tumor suppressor implicated in several types of cancers. However, its relationship to breast cancer is still unknown. The present study aimed to assess the association of p16 protein expression with clinicopathological features in breast cancer.

This study aimed to investigate the anti-cancer effects of different gum extracts on metabolic changes and their impact on gene expression in HT-29 cell.

Methods: The study enrolled 100 patients with invasive ductal carcinoma. The samples were collected before any adjuvant chemotherapy, and p16 protein expression was determined using immunohistochemistry. Clinicopathological features were obtained from the patient's medical records.

Results: Our findings demonstrated that p16 protein expression increased in estrogen receptor-positive tumor tissues ($P < 0.01$). However, no significant correlation was found between the p16 protein expression and the other clinicopathological features.

Conclusions: Our study demonstrated that p16 protein expression increased in ER-positive tumor tissue from patients with invasive ductal breast carcinoma. However, no correlation was found between the p16 protein expression and the other clinicopathological features.

Keywords: Breast cancer, Immunohistochemistry, Prognostic factor, P16.

Introduction

Breast cancer is one of the leading causes of cancer deaths in women (1). According to the World Health Organization (WHO), about 2.3 million new cases of breast cancer and 685,000 deaths from this disease were recorded in 2020 worldwide (2). It is predicted that 3.2 million new cases of breast cancer will be diagnosed annually by 2050 (3). Breast cancer is a multifactorial heterogeneous disease, and genetic susceptibility plays a significant role in prognosis and clinical management decisions (4, 5). This cancer can develop from the epithelium of the glandular ducts (ductal carcinoma) or lobules (lobular carcinoma)

and spread to other organs via the lymphatic system or bloodstream (6). about 30 percent of women diagnosed with invasive breast cancer would develop metastasis and despite advancements of cancer screening and treatment, the high mortality rate of these patients highlights the importance of early detection (7, 8). Nevertheless, breast cancer prognosis is challenging because cancer cell behavior varies considerably between patients (9). Today, several markers such as human epidermal growth factor 2 (HER2), estrogen receptor (ER), progesterone receptor (PR), and Ki67 are used as the prognostic factors (10, 11). The p16 protein is a cell cycle

1: Department of Pathology, Faculty of Medicine, Islamic Azad University, Mashhad Branch, Mashhad, Iran.

*Corresponding author: Negin Ghiyasi-Moghaddam; Tel: +98 9151247031; E-mail: neginghm74@gmail.com.

Received: 8 Mar, 2023; Accepted: 8 May, 2023

regulator and tumor suppressor which is encoded by the cyclin-dependent kinase inhibitor 2A gene (*CDKN2A*) on chromosome 9p21 (12, 13). The p16 protein prevents the transition from G₁ to the DNA synthesis phase (G₁/S) by disrupting the cyclin-dependent kinase 4 (CDK4)/cyclin D1 (CCND1) interaction and subsequent retinoblastoma protein (RbP) phosphorylation (14, 15). Normal tissues have low or undetectable levels of the p16 protein. Its overexpression has been reported in several types of cancers, suggesting that it may be a response to malignancy (16-19). In contrast, several studies have revealed that p16 suppression by DNA mutation, deletion, or promoter hypermethylation is associated with various malignancies, such as melanoma, hepatocarcinoma, cervical cancer, and esophageal carcinoma (20, 21). Nevertheless, the prognostic significance of p16 expression in breast cancer is unclear (22). As a result, this study evaluated the relationship between p16 expression and clinicopathological characteristics in invasive ductal breast carcinoma.

Materials and Methods

Ethics statement

This study was carried out in accordance with the Helsinki Declaration's ethical principles for human clinical research (23). The Ethics Committee of the Islamic Azad University, Mashhad Branch, Iran, also approved the research protocol (approval no. IR.IAU.MSHD.REC.1398.116). In addition, participants were informed about the study's objectives and provided informed consent to participate.

Patients

This descriptive-analytical cross-sectional study included 100 women with invasive ductal breast carcinoma who were admitted to a medical diagnostic laboratory in Mashhad, Iran, between 2018 and 2020. The inclusion criteria were: 1) diagnosis of invasive ductal breast carcinoma based on core needle biopsy, 2) ability to access patient pathology and

immunohistochemical information, and 3) ability to provide informed consent. Patients with a history of neoadjuvant chemotherapy were excluded from the study.

Data collection

Clinicopathological features such as tumor grade, tumor size, HER2, ER, PR, and Ki67 status were collected from the patient's medical records using a standardized protocol. In the same way, demographic characteristics such as age, menarche age, number of pregnancies, family history of breast cancer, and hormonal oral contraceptive use of the patients were recorded. Furthermore, the semi-quantitative method for assessing histological grade in breast carcinoma was used for cancer grading.

Immunohistochemistry

Immunohistochemistry was used to measure the expression of the p16 protein. Three μm -thick sections were cut from paraffin blocks and transferred to clean adhesive slides. All tissue sections were de-waxed with Xylene (Sigma Aldrich, Germany) and rehydrated by serial immersion in descending alcohol. Before immunohistochemical staining, tissue sections were incubated in EDTA-Tris buffer saline (Merck, Germany) for 20 minutes at 98 °C to allow antigens to be retrieved. After washing with Tris-buffered saline (TBS) (Merck, Germany) and immersing in H₂O₂ 3% (Leica Biosystem, Germany), the slides were incubated for 25 min at 25 °C with p16 primary antibody solutions (Master Diagnostica, Spain). The slides were then rinsed with TBS and incubated for 20 minutes with a post-primary block (Leica Biosystem, Germany) before being treated with Novolink™ Polymer (Leica Biosystem, Germany) for another 20 minutes. In the negative control, the primary antibody incubation step was skipped. The slides were dyed with diaminobenzene peroxidase (Leica Biosystem, Germany) and counterstained with hematoxylin for 5 and 2 minutes, respectively. Finally, specimens were dehydrated in ascending alcohol, cleared in Xylene, and mounted in Canada balsam

(Sigma-Aldrich) for light microscopy analysis (24). The staining rate of the slides was graded from zero to four, with grade 0: indicating that the slides were stained less than 10%, grade 1: between 10% and 25%, grade 2: between 25% and 50%, grade 3: between 50% and 70%, and grade 4: indicating that the slides were stained more than 70%. Furthermore, grades 1 and 2 were considered low-positive, while grades 3 and 4 were considered high-positive (25). We categorized breast cancer phenotypes based on ER, PR, HER-2, and Ki67 immunostaining (26).

Statistical analysis

Statistical analysis was performed by SPSS Statistics 25.0 software (SPSS Inc., Chicago, Illinois, USA). All the descriptive and quantitative data were expressed as percentages and the mean \pm standard deviation (SD), respectively. The Pearson chi-square test was used to determine the relationship between qualitative variants. The intergroup comparison was carried out by analysis of variance (ANOVA) after determining the normality of the quantitative data distribution using the Kolmogorov-Smirnov test. P-values less than 0.05 were considered statistically significant.

Results

Demographic and Clinicopathological Features

The demographic evaluation showed that the average age of the patients was 49 ± 12.54 years and their mean menarche age and number of pregnancies were 13 ± 1.3 years (range 9 to 16) and 3.6 ± 2.4 (range 0 to 12), respectively. Moreover, 42% of patients had used hormonal oral contraceptives, and 21% had a family history of breast cancer. According to the semi-quantitative method for assessing histological grade, eight patients were diagnosed with grade I breast cancer, 74 with grade II breast cancer, and 18 with grade III breast cancer and the tumor diameter ranged from 6 mm to 56 mm, with a 24 ± 10.22 mm average.

Immunohistochemistry

Immunohistochemical staining of P16 protein expression in patients revealed that 29 patients (29%) were negative for p16 protein expression, 44 (44%) were low-positive, and 27 (27%) were high-positive. Furthermore, the results showed that 80 patients (80%) were ER-positive, 63 (63%) were PR-positive, and 30 (30%) were HER2-positive. Also, Ki67 expression was found to be less than 14% in 28 patients and greater than 14% in 72 patients (Fig. 1).

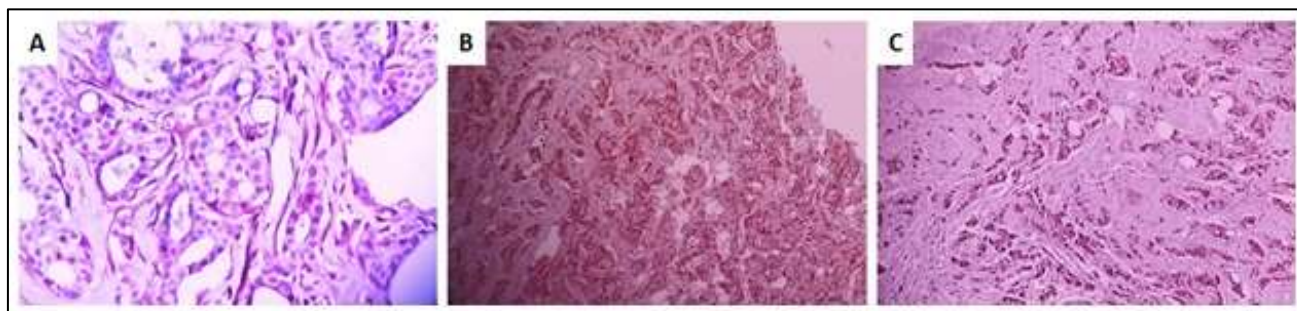


Fig. 1. Immunohistochemical staining for p16 protein in invasive ductal breast tumors. A. p16 negative, B. p16 low positive, C. High-positive.

Association of P16 Protein Expression with Clinicopathological Features

Immunohistochemical analysis was used to examine p16 protein expression in cancerous tissues and its relationship to clinicopathological features. As shown in Table 1, the Pearson chi-square analysis showed a statistically significant correlation between p16 expression and ER expression

($P < 0.01$) but, there was no significant association between the p16 protein and PR expression.

Table 2 compares p16 protein expression in terms of patient age and tumor size. ANOVA revealed no significant differences in age or tumor size between patients with negative p16, low-positive p16, and high-positive p16. In our study, tumors were divided into three groups

based on their size: ≤ 20 mm, 21 to 50 mm, and > 50 mm. As shown in Table 1, a Pearson chi-square comparison of p16 expression in patients with different tumor sizes has no significant difference. Besides that, based on immunostaining for ER, PR, HER-2, and Ki67, the cancer phenotypes were classified into luminal A, luminal B, HER-2 positive, and triple-negative, the luminal B group exhibited the highest negative and positive rates for p16 protein expression compared to other breast

cancer phenotypes. However, Pearson chi-square analysis revealed that p16 protein expression was not significantly different across breast cancer phenotypes. These findings suggest that there was no association between p16 expression and patient age, cancer type, and tumor size (Table 2). Similarly, there was no significant correlation between p16 expression with HER2, Ki67, cancer grade, or family history of breast cancer (Table 1).

Table 1. Correlation between clinicopathological characteristics and p16 protein expression in women with invasive ductal breast carcinoma.

Parameters	P16 Protein Expression Level			P-value (Chi-Square)	
	Negative	Low-Positive	High-Positive		
ER receptor	Positive	22 (75.9%)	41 (93.2%)	17 (63%)	0.007*
	Negative	7 (24.1%)	3 (6.8%)	10 (37%)	
PR receptor	Positive	14 (48.3%)	33 (75%)	16 (59.3%)	0.061
	Negative	15 (51.7%)	11 (25%)	11 (40.7%)	
HER2	Positive	4 (13.8%)	15 (34.1%)	11 (40.7%)	0.065
	Negative	25 (86.2%)	29 (65.9%)	16 (59.3%)	
Ki67	Positive ($> 14\%$)	7 (24.1%)	16 (36.4%)	5 (18.5%)	0.229
	Negative ($\leq 14\%$)	22 (75.9%)	28 (63.6%)	22 (81.5%)	
Cancer Grade	I	2 (6.9%)	2 (4.5%)	4 (14.8%)	0.252
	II	20 (69%)	37 (84.1%)	17 (6%)	
	III	7 (24.1%)	5 (11.4%)	6 (22.2%)	
Tumor Size	≤ 20 mm	11 (37.9%)	18 (40.9%)	13 (48.1%)	0.754
	21-50 mm	18 (62.1%)	25 (56.8%)	14 (51.9%)	
	> 50 mm	0 (0%)	1 (2.3%)	0 (0%)	
Cancer Type	Luminal A	7 (29.16%)	13 (54.16%)	4 (16.66%)	0.144
	Luminal B	15 (26.31%)	28 (49.12%)	14 (24.56%)	
	HER2 positive	2 (28.57%)	1 (14.28%)	4 (57.14%)	
	Triple Negative	5 (41.66%)	2 (16.66%)	5 (41.66%)	
Age	≤ 40 years	7 (24.1%)	11 (25%)	10 (37%)	0.471
	> 40 years	22 (75.9%)	33 (75%)	17 (63%)	
Family History	Yes	5 (17.2%)	11 (25%)	5 (18.5%)	0.68
	No	24 (82.8%)	33 (75%)	22 (81.5%)	

The data are shown as mean \pm SD. ** $P < 0.01$. (HER2: human epidermal growth factor 2, ER: the estrogen receptor, PR: progesterone receptor).

Table 2. Correlation of p16 expression with tumor grade and age of patients with invasive ductal breast carcinoma. The data are shown as mean \pm SD.

Age of Patients (years)	Number	Minimum	Maximum	Mean \pm SD	P-value
Negative	29	28	80	51.52 \pm 13.33	
Low-Positive	44	28	78	49.36 \pm 12.69	0.414
High-Positive	27	31	76	47.04 \pm 11.41	
Tumor Size (mm)					
Negative	29	10	40	23.85 \pm 7.4	0.846
Low-Positive	44	6	56	23.97 \pm 10.93	
High-Positive	27	9	48	25.26 \pm 11.83	

Discussion

The current study was conducted to determine the relationship between p16 protein expression and clinicopathological features in 100 women diagnosed with invasive ductal breast carcinoma. The obtained results showed no significant association between the p16 protein and PR expression. Also, no relation between p16 expression and patient age, cancer type, and tumor size was found. Moreover, the correlation between p16 expression with HER2 and Ki67 expression was not significant.

Several studies investigated the prognostic impact of the p16 protein expression pattern in various malignancies (22, 27, 28). Some studies have suggested that p16 protein dysfunction may contribute to the development of breast cancer (19, 22). However, the role of the p16 protein in breast cancer development and progression is not clear yet. As a result, this study aimed to investigate the relationship between the level of p16 protein expression in women with invasive ductal breast carcinoma and its clinicopathologic implications. Because immunohistochemistry can detect the p16 protein in both the nuclear and cytoplasmic regions of cells, we used it to stain the p16 protein in tumor tissues (29). Our findings revealed that 29 patients (29%) were P16 negative and 71 (71%) were P16 positive, with 44 having low P16 expression and 27 having high P16 expression. Similarly, an immunohistochemistry study by *Shin et al.* (2015) on 406 women with invasive breast cancer found that 31 patients (7.6%) had negative P16 expression, 212 (52.2%) with low P16 expression, and 163 (40.1%) with high P16 expression (30). Moreover, in an immunohistochemical study of breast cancer, *Golmohammadi et al.* found p16 expression in 82% of patients (31). In both studies, the prevalence of p16 expression was comparable to our findings. Moreover, Table 1 shows that of the 80 ER-positive patients in our study, 58 patients (72.5%) were p16 positive, with 41 low- positive p16 cases and 17 high- positive

p16 cases. Pearson chi-square analysis revealed that p16 protein expression was correlated with ER expression in breast carcinoma tissues ($P < 0.01$) but not with PR expression. Concerning the relationship between p16 expression and ER, some studies suggested that high levels of p16 protein expression were associated with ER-negative and PR-negative phenotypes in breast carcinoma, which contradicts our findings (18, 30, 32). Although we found no correlation between p16 protein expression and tumor grade or size (Table 1), but *Peurala et al.* (2013) reported that p16 expression is significantly greater in high-grade tumors in a study evaluating the prognostic significance of p16 in human breast cancer (33). Similarly, *Golmohammadi et al.* (2017) observed that all grade III tumors were p16 positive and expressed more p16 than other tumor grades (31). Also, *Salih et al.* (2022) concluded that p16 protein expression was associated with high histologic grade and could be used as a prognostic marker (22). Regarding tumor size, some studies have revealed no correlation between p16 expression and tumor size in breast cancer, which supports our findings (34, 35). In contrast, *Zhao et al.* (2015) provided a correlation between p16 protein expression and tumor size in an immunohistochemistry-based study. They discovered that p16 expression was significantly higher in tumors ≤ 20 mm in size compared to tumors > 50 mm (36). On the other hand, there is some evidence that p16 protein expression is increased in advanced breast cancer and high-grade tumors (18, 37, 38). Although p16 is a tumor suppressor, it may help accelerate tumor growth by activating certain genes involved in cancer tissue angiogenesis. (31, 39). Cancer phenotypes in the present study were classified as luminal A, luminal B, HER-2, and triple-negative. Our results showed that p16 protein expression was not significantly different among breast cancer phenotypes. Furthermore, no correlation was found between p16 expression and cancer type (Table 1). In

contrast to our findings, *Bohn et al.* (2010) and *Jour et al.* (2016) found that patients with triple-negative breast cancer had significantly higher p16 protein expression (40, 41). *Shin et al.* (2015) also found that p16 protein expression was significantly higher in patients with, luminal B, and HER2 breast cancer (30). In another study, *Peurala et al.* (2013) showed high expression of p16 in the HER2 negative phenotype (33). *Langosch et al.* (2001) found no significant correlation between p16 and HER2 expression levels, which is consistent with our findings (18). In addition, *Kobierzycki et al.* (2018) reported no relationship between p16 expression and Ki67 (42), whereas *Shan et al.* (2013) revealed a decrease in p16 protein expression in ki67-positive breast cancer cells (34). According to our findings, Ki67 expression, a known malignant tumor proliferation index, was less than 14% in 28 patients and greater than 14% in 72 patients. However, we did not find any statistically significant relationship between P16 protein expression and the ki67 marker (Table 1). In terms of the correlation between p16 expression and patient age, our findings indicated that there was none. Some studies, however, have found that p16 expression is associated with the age of breast cancer patients. For instance, *Shan et al.* (2013) found that low levels of P16 expression were associated with older age (34). In agreement with our findings, *Pare et al.* (2016) concluded that there is no significant relationship between p16 protein expression and the age of breast cancer patients (35). In terms of the effect of breast cancer family history on p16 expression pattern, *Askari et al.* (2013) demonstrated that *CDKN2A* methylation was significantly higher in patients with a breast cancer family history compared to patients without a family history (43). Some evidence suggests that *CDKN2A* promoter hypermethylation decreases p16 protein expression in breast cancer (44). In line with our findings, *Bartova et al.* (2014) found no significant association between p16 and a family history of breast cancer (45).

In summary, previous studies on p16 protein dysfunction and poor survival in breast cancer patients were inconclusive. On the other hand, our study found no prognostic significance for p16 protein expression in invasive ductal breast carcinoma. However, given the small sample size and short follow-up period, our findings should be interpreted with caution. As a result, additional research is likely required. The failure to assess the relationship between p16 expression and menarche age, menopausal age, the number of pregnancies, and the use of hormonal contraception pills was one of the study's limitations. Another limitation was the inability to assess patients' survival and quality of life because of the COVID-19 pandemic.

In conclusion, our findings demonstrated that p16 protein expression increased in ER-positive tumor tissue from patients with invasive ductal breast carcinoma. However, no correlation was found between the p16 protein expression and the other clinicopathological features. We believe that immunohistochemical detection of the p16 protein could be a useful preliminary screening assay for predicting patient prognosis. but more research in other cohorts is required to determine the prognostic value of the p16 protein in breast cancer.

Acknowledgement

All authors thank the Department of Pathology, Faculty of Medicine, Islamic Azad University, Mashhad Branch, Mashhad, Iran.

Funding

This work was supported by the Department of Pathology, Faculty of Medicine, Islamic Azad University, Mashhad Branch, and supported the project financially (Grant number: 162256189).

Conflict of Interest

The authors declare that they have no competing interests.

References

1. Katuwal S, Jousilahti P, Pukkala E. Causes of death among women with breast cancer: A follow-up study of 50 481 women with breast cancer in Finland. *Int J Cancer*. 2021;149(4):839-45.
2. Hasan SAW. World Health Organization WHO Regional websites. Primary health care. 2021.
3. Tao Z, Shi A, Lu C, Song T, Zhang Z, Zhao J. Breast cancer: epidemiology and etiology. *Cell Biochem Biophys*. 2015;72(2):333-8.
4. Mavaddat N, Antoniou AC, Easton DF, Garcia-Closas M. Genetic susceptibility to breast cancer. *Mol Onc*. 2010;4(3):174-91.
5. Choi J, Jia G, Wen W, Tao R, Long J, Shu X-O, et al. Associations of genetic susceptibility to 16 cancers with risk of breast cancer overall and by intrinsic subtypes. *Hum Gen Genom Adv*. 2022;3(1):100077.
6. Bal A, Joshi K. Pathology of Breast Cancer. *Breast Cancer: Springer*; 2022: 125-38.
7. Scully OJ, Bay B-H, Yip G, Yu Y. Breast cancer metastasis. *Cancer Genom Proteom*. 2012;9(5):311-20.
8. Oppenheimer SB. Cellular basis of cancer metastasis: A review of fundamentals and new advances. *Acta histochemica*. 2006;108(5):327-34.
9. Löönd F, Tiede S, Christofori G. Breast cancer as an example of tumour heterogeneity and tumour cell plasticity during malignant progression. *Br J Cancer*. 2021;125(2):164-75.
10. Zhao X, Yang X, Fu L, Yu K. Associations of Estrogen Receptor, Progesterone Receptor, Human Epidemic Growth Factor Receptor-2 and Ki-67 with Ultrasound Signs and Prognosis of Breast Cancer Patients. *Cancer Manag Res*. 2021;13:4579.
11. Choi SB, Park JM, Ahn JH, Go J, Kim J, Park HS, et al. Abstract P2-08-13: The prognostic significance of Ki67 and progesterone receptor; could they really have prognostic importance in early breast cancer with estrogen receptor positive, HER-2 negative?. *Cancer Res*. 2022; 82 (4_Supplement): P2-08-13.
12. Xia Y, Liu Y, Yang C, Simeone DM, Sun T-T, DeGraff DJ, et al. Dominant role of CDKN2B/p15INK4B of 9p21. 3 tumor suppressor hub in inhibition of cell-cycle and glycolysis. *Nat commun*. 2021;12(1):1-15.
13. Spiliopoulou P, Yang SYC, Bruce JP, Wang BX, Berman HK, Pugh TJ, Siu LL. All is not lost: learning from 9p21 loss in cancer. *Trends Immunol*. 2022;43(5):379-390.
14. Hume S, Dianov GL, Ramadan K. A unified model for the G1/S cell cycle transition. *Nucleic Acids Res*. 2020;48(22):12483-501.
15. Julve M, Clark JJ, Lythgoe MP. Advances in cyclin-dependent kinase inhibitors for the treatment of melanoma. *Expert Opin Pharmaco*. 2021;22(3):351-61.
16. Shigemasa K, Hu C, West C, Clarke J, Pharham G, Parmley T, et al. p16 overexpression: a potential early indicator of transformation in ovarian carcinoma. *J Soc Gynecol Invest*. 1997;4(2):95-102.
17. Mai S, Welzel G, Ottstadt M, Lohr F, Severa S, Prigge E-S, et al. Prognostic relevance of HPV infection and p16 overexpression in squamous cell anal cancer. *nt J Rad Oncol Biol Phys*. 2015;93(4):819-27.
18. Milde-Langosch K, Bamberger A-M, Rieck G, Kelp B, Löning T. Overexpression of the p16 cell cycle inhibitor in breast cancer is associated with a more malignant phenotype. *Breast Cancer Res Treat*. 2001;67(1):61-70.

19. Hashmi AA, Naz S, Hashmi SK, Hussain ZF, Irfan M, Khan EY, et al. Prognostic significance of p16 & p53 immunohistochemical expression in triple negative breast cancer. *BMC Clin Pathol.* 2018;18(1):1-11.
20. El-shaarawy F, Abo ElAzm MM, Mohamed RH, Radwan MI, Abo-Elmatty DM, Mehanna ET. Relation of the methylation state of RUNX3 and p16 gene promoters with hepatocellular carcinoma in Egyptian patients. *Egypt J Med Hum Genet.* 2022;23(1):1-9.
21. Inoue K, Fry EA. Aberrant expression of p14ARF in human cancers: A new biomarker? *Tumor microenvironment.* 2018;1(2):37.
22. Salih MM, Higgs AA, Eed EM. Prognostic Significance of p16 Protein Expression in Breast Cancer. *in vivo.* 2022;36(1):336-40.
23. Shrestha B, Dunn L. The declaration of helsinki on medical research involving human subjects: A review of seventh revision. *J J Nepal Health Res Council.* 2019;17(4):548-52.
24. Lee K, Jung ES, Choi Y-J, Lee KY, Lee A. Expression of pRb, p53, p16 and cyclin D1 and their clinical implications in urothelial carcinoma. *J Korean Med Sci.* 2010;25(10):1449-55.
25. Shariat SF, Tokunaga H, Zhou J, Kim J, Ayala GE, Benedict WF, et al. p53, p21, pRB, and p16 expression predict clinical outcome in cystectomy with bladder cancer. *J Clin Oncol.* 2004;22(6):1014-24.
26. Goldhirsch A, Wood WC, Coates AS, Gelber RD, Thürlimann B, Senn H-J. Strategies for subtypes—dealing with the diversity of breast cancer: highlights of the St Gallen International Expert Consensus on the Primary Therapy of Early Breast Cancer 2011. *Ann Oncol.* 2011;22(8):1736-47.
27. Park JW, Kang J, Lim KY, Kim H, Kim S-I, Won JK, et al. The prognostic significance of p16 expression pattern in diffuse gliomas. *J Transl Med.* 2021;55(2):102.
28. Rambau PF, Vierkant RA, Intermaggio MP, Kelemen LE, Goodman MT, Herpel E, et al. Association of p16 expression with prognosis varies across ovarian carcinoma histotypes: an Ovarian Tumor Tissue Analysis consortium study. *J Pathol Clin Res.* 2018;4(4):250-61.
29. Witkiewicz AK, Knudsen KE, Dicker AP, Knudsen ES. The meaning of p16ink4a expression in tumors: functional significance, clinical associations and future developments. *Cell cycle.* 2011;10(15):2497-503.
30. Shin E, Jung W-H, Koo J-S. Expression of p16 and pRB in invasive breast cancer. *Int J Clin Exp Pathol.* 2015;8(7):8209.
31. Golmohammadi R, Elyasi H. Relationship between P16 expression and breast cancer using histology and immunohistochemistry. *J Mazandaran Uni Med Sci.* 2017;27:181–186.
32. Zhang S-L, Wang Y-Q, Zhang J-H, Hu J-W, Ma J, Gu Z, et al. Methylated p16 gene is associated with negative expression of estrogen receptor, progesterone receptor and human epidermal growth factor receptor 2 in breast cancer. *Eur J Gynaecol Oncol.* 2021;42(3):530-6.
33. Peurala E, Koivunen P, Haapasaari K-M, Bloigu R, Jukkola-Vuorinen A. The prognostic significance and value of cyclin D1, CDK4 and p16 in human breast cancer. *Breast Cancer Res.* 2013;15(1):1-10.
34. Shan M, Zhang X, Liu X, Qin Y, Liu T, Liu Y, et al. P16 and p53 play distinct roles in different subtypes of breast cancer. *PloS one.* 2013;8(10):e76408.
35. Pare R, Shin JS, Lee CS. Increased expression of senescence markers p14ARF and p16INK4a in breast cancer is associated with an increased risk of disease recurrence and poor survival outcome. *Histopathology.* 2016;69(3):479-91.
36. Zhao L, Liu H. Immunohistochemical detection and clinicopathological significance of JARID1B/KDM5B and P16 expression in invasive ductal carcinoma of the breast. *Genet Mol Res.* 2015;14(2):5417.
37. Vohra L, Siddiqui T. Metaplastic Breast Cancer and p16 Positivity: What Does It Mean. *J Carcinog Mutagene.* 2015;6(6):244.
38. Lebok P, Roming M, Kluth M, Koop C, Özden C, Taskin B, et al. p16 overexpression and 9p21 deletion are linked to unfavorable tumor phenotype in breast cancer. *Oncotarget.* 2016;7(49):81322.

39. Zhu L-F. The correlation of p16 and MMPs expression in cervical secretions with the angiogenesis and cell proliferation in cervical cancer tissue. *J Hainan Med Univ.* 2017;23(8):130-3.
40. Bohn OL, Fuertes-Camilo M, Navarro L, Saldivar J, Sanchez-Sosa S. p16INK4a expression in basal-like breast carcinoma. *Int J Clin Exp Pathol.* 2010;3(6):600.
41. du Jour KS, Geller R, Dureau ZJ, Liu Y, Cohen C, Oprea-Ilies GM, editors. p16 Is Highly Expressed in TNT and Is Associated with Worse Overall Survival (OS) in All Breast Cancers (BC). Laboratory Investigation; 2016: Nature Publishing Group 75 Varick St, 9th Flr, New York, NY 10013-1917 USA.
42. Kobierzycki C, Grzegorzolka J, Glatzel-Plucinska N, Piotrowska A, Wojnar A, Smolarz B, et al. Expression of p16 and SATB1 in Invasive Ductal Breast Cancer—A Preliminary Study. *In Vivo.* 2018;32(4):731-6.
43. Askari M, Sobti RC, Nikbakht M, Sharma SC. Promoter hypermethylation of tumour suppressor genes (p14/ARF and p16/INK4a): case–control study in North Indian population. *Mol Biol Rep.* 2013;40(8):4921-8.
44. Bhatia K, Misra P, Soe YN, Sibin MK, Batra HS, Shelly D, et al. A pilot study on DNA hypermethylation status in promoter region of P16 gene in patients with sporadic breast cancer. *Med J Armed Forces India.* 2022 Jul;78(3):322-326.
45. Bartova M, Ondrias F, Muy-Kheng T, Kastner M, Singer Ch, Pohlodek K. COX-2, p16 and Ki67 expression in DCIS, microinvasive and early invasive breast carcinoma with extensive intraductal component. *Bratisl Lek Listy.* 2014;115(7):445-51.